

Elective Clinical Target Volumes in Anorectal Cancer: An RTOG Consensus Panel Contouring Atlas

R Myerson¹, M Garofalo², Iel Naqa¹, R Abrams³, A Apte¹, W Bosch¹, P Das⁴, L Gunderson⁵, T Hong⁶, J Kim⁷, C Willett⁸, L Kachnic⁹

**From the Departments of Radiation Oncology: ¹Washington University ,
²University of Maryland Medical Center, ³Rush University Medical Center, ⁴UT,
MD Anderson Cancer Center, ⁵Mayo Clinic, Scottsdale AZ, ⁶Massachusetts General
Hospital, ⁷Princess Margaret Hospital, University of Toronto, ⁸Duke University,
⁹Boston University Medical Center**

Introduction

The advent of intensity modulated radiotherapy (IMRT) provides an opportunity to spare critical normal tissue. For patients receiving radiotherapy for anal or rectal cancer, small bowel and the femoral heads can often be better protected with IMRT than conventional techniques. However, the technology also presents a challenge to the radiation oncologist. IMRT demands a much more detailed understanding of target structures than a conventionally planned two to four field technique.

Target volumes for anal and rectal cancer differ substantially from those appropriate for gynecologic or genitourinary cancer. The most striking differences arise from the need for proper coverage of the peri-rectal and pre-sacral regions. The rectum and its associated mesentery are avoidance structures for GYN or GU malignancy, but represent first echelon drainage for both the anus and rectum.

The atlas that follows was produced by a consensus committee of nine radiation oncologists (RA, PD, MG, LG, TH, LK, JK, RM, CW). The formation of the group was motivated, in part, by what was felt to be inadequate contouring in a large number of cases enrolled on RTOG 0529 (A Phase II Evaluation of Dose-Painted IMRT in Combination with 5-Fluorouracil and Mitomycin-C for Reduction of Acute Morbidity in Carcinoma of the Anal Canal). The most common revisions were to correct incomplete coverage of the peri-rectal and pre-sacral regions. Because of a rapid submission and review process, patient care was not compromised, but an educational need was identified. The consensus group was established by the Gastrointestinal Committee of the RTOG and was chaired by principal investigators and co-investigators of existing or soon to be activated clinical trials evaluating intensity modulated radiotherapy (IMRT) in the management of anal (LK and RM) and rectal carcinoma (MG).

Contoured Elective Clinical Target Volumes

Members of the resulting consensus group were asked to help determine specific contouring examples and answer detailed questions about three elective clinical target volumes (CTVs):

CTVA: For this atlas, defined to be the regions that would always be treated for rectal cancer: internal iliac, pre-sacral, peri-rectal.

CTVB: external iliac nodal region

CTVC: inguinal nodal region

For anal cancers, the elective regional target volume would include all three. For rectal cancer, in most cases, CTVA would be the only volume to receive elective radiation. However, for certain presentations (e.g. extension into GU structures, extension to the peri-anal skin) one could consider adding the external iliac (CTVB) and even the inguinal regions (CTVC).

Methodology

The case utilized for this atlas was a clinical T3 N2 rectal cancer located 7 cm above the verge. The case was selected because of the presence of multiple peri-rectal lymph nodes, without major distortion of the mesorectum. For reasons unrelated to the rectal cancer, this case also had multiple small inguinal and external iliac lymph nodes, which inform the process of outlining CTVB and CTVC. The patient was simulated in the prone position, with a flexible endorectal tube placed at the distal edge of palpable disease and a skin marker placed 4 cm below the distal edge of palpable disease.

The consensus generating process consisted of answering a series of questions as well as contouring the target structures. The imaging files were shared via the Advanced Technology Consortium, with each participant using his/her own treatment planning system to contour. A program developed by Dr. el Naqa utilized the binomial distribution to generate a 95% group consensus contour. The computer-estimated consensus contours were then reviewed by the group and modified to provide final contours.

Results

In **Figure 1**, the individual contourers submissions are superimposed and displayed on four representative slices. In general there is good agreement on the location of the core portions of the mesorectum as well as the iliac and femoral vessels. For CTVA, differences between individual contourers were primarily a matter of margin. Therefore, for this target volume the group agreed to accept the computer generated consensus contours. For CTVB and C, the group felt that small lymph nodes, if present, should be incorporated into the target volume, even if it was felt that they were probably

uninvolved reactive nodes. Including nodes that were missed by some of the contourers led to modifications of the computer generated contours. The agreed upon extensions was primarily into the lateral inguinal regions.

The resulting consensus contours are displayed in **Figure 2**.

Specific details decided through the consensus process include the following.

Group Recommendations: CTVA (peri-rectal, pre-sacral, internal iliac regions)

Lower Pelvis: The caudad extent of this elective target volume should be a minimum of 2 cm caudad to gross disease, including coverage of the entire mesorectum to the pelvic floor (located at slice -40.78 in the sample case) even for upper rectal cancers. For anal cancer this implies that the elective target volume should extend at least 2 cm around the anal verge or areas of peri-anal skin involvement (in RTOG 0529 the requirement is 2.5 cm). For this sample case of a mid-rectal cancer, the caudad extent of CTVA is at slice -42.58, because that slice is 2 cm caudad to the distal extent of palpable disease (defined by the tube placed in the rectum). If this had been an upper rectal cancer, the caudad extent of CTVA could not go above slice -41.08 (pelvic floor).

The group agreed that, unless there is radiographic evidence of extension into the ischiorectal fossa, extension of CTVA does not need to go more than a few millimeters beyond the levator muscles. For very advanced anal or rectal cancers, extending through the mesorectum or the levators, the group's recommendation is to add ~1-2 cm margin up to bone wherever the cancer extends beyond the usual compartments. An MRI and/or PET/CT scan is strongly recommended in such cases.

Mid pelvis: The posterior and lateral margins of CTVA should extend to lateral pelvic sidewall musculature or, where absent, the bone. Anteriorly, the group recommended extending CTVA to ~1 cm into the posterior bladder, to account for day-to-day variation in bladder position. Also in the mid pelvis, the group recommended including at least the posterior portion of the internal obturator vessels (which lie between the external and internal iliacs in the mid pelvis) with CTVA.

Upper pelvis: The recommended superior extent of the peri-rectal component of CTVA was at whichever is more cephalad: the rectosigmoid junction or 2 cm proximal to the superior extent of macroscopic disease in the rectum/peri-rectal nodes. This defines how much of the distal large bowel should be within CTVA. The most cephalad extent of CTVA will be higher than the peri-rectal component, in order to properly cover the internal iliac and pre-sacral regions. The most cephalad aspect of CTVA should be where the common iliac vessels bifurcate into external/internal iliacs (approximate boney landmark: sacral promontory).

Group Recommendations: CTVB (external iliac region) and CTVC (inguinal region)

Indications for elective irradiation: The consensus group felt that elective coverage of the inguinal and external iliac regions should be routine for anal carcinoma. There was some disagreement as to the indications for covering these regions for rectal carcinomas. For rectal carcinomas extending into gynecologic or genitourinary structures, the group agreed that the external iliac region should be added (i.e. elective nodal coverage = CTVA + CTVB for these cases). Some, but not all, of the committee would also include the external iliacs for rectal cancers that extend into the anal canal. Similarly, the group was divided on whether to electively irradiate the inguinal nodal region for rectal adenocarcinomas that extend to the anal verge or peri-anal skin.

Caudal extent of elective target volumes: The group recommended that the caudal extent of the inguinal region (CTVC) should be 2 cm caudad to the saphenous/femoral junction. The transition between inguinal and external iliac regions (CTVC to CTVB) is somewhat arbitrary, but the group recommended the level of the bottom of the internal obturator vessels (approximate boney landmark: upper edge of the superior pubic rami).

Margin around blood vessels: The group recommended a 7-8 mm margin in soft tissue around the external iliac vessels, but one should consider a larger 10+ mm margin anterolaterally—especially if small vessels or nodes are identified in this area. The inguinal/femoral region should be contoured as a compartment with any identified nodes (especially in the lateral inguinal region) included.

Group Recommendations: Boost Volumes

The group opted not to include boost target volumes in this atlas. This was felt to be something that might be defined differently in different protocols, might be affected by evolving imaging capabilities, and vary sharply from one patient to the next. The group did recommend that any boost clinical target volumes extend to entire mesorectum and presacral region at involved levels, including ~2 cm cephalad and caudad in the mesorectum and ~2 cm on gross tumor within the anorectum.

Similarly this atlas does not present planning target volumes (PTVs). It was generally agreed that the PTV margin should be ~0.7 to 1.0 cm, except at skin.

Group Recommendations: Normal Tissues

Although normal tissues were not contoured in this atlas, there were several general recommendations by the group.

The femoral head and neck should be avoidance structures.

The small and large bowel are important structures to consider when planning treatment. To avoid unnecessary time spent contouring the entire abdominal contents, they only need to be contoured up to ~ 1 cm above the PTV. This, in turn, implies that absolute volume of bowel (in cc) is more important than relative volume (in %). Otherwise cases with good exclusion of small bowel from the pelvis (e.g. with a belly board) will be unfairly penalized.

The panel felt that it is important that dose volume histograms be consistent from one contourer to the next. Therefore we recommended that bowel be contoured tightly, rather than with a broad, ill-defined margin. It is recognized that the location of bowel could vary from one day to the next, but the dose volume histogram (DVH) from the simulation should remain representative. It was suggested that a broader avoidance structure could be used for IMRT planning purposes (e.g. anterior pelvic contents above the bladder and ~ 1 cm outside the PTVs), while the tightly contoured bowel would remain the structure evaluated in the DVHs.

With regard to large bowel, it is very important to recognize that all of the rectum and much of the rectosigmoid will be part of CTVA and, therefore, should NOT be treated as an avoidance structure. Therefore, it is recommended that “uninvolved colon”, defined to be that part of the large bowel that lies outside the CTVs, be contoured separately from the rectum.

Note that, if small bowel happens to lie within a CTV (see slices –30.88 to –36.28 of this sample case), the CTV is NOT modified and the portion of small bowel that fell within the target volume is NOT extracted from the DVHs.

FIGURE 1. Superposition of individual investigator's contours of clinical target volumes. Each contourer was assigned a different color. These are best viewed with a zoom of 200%

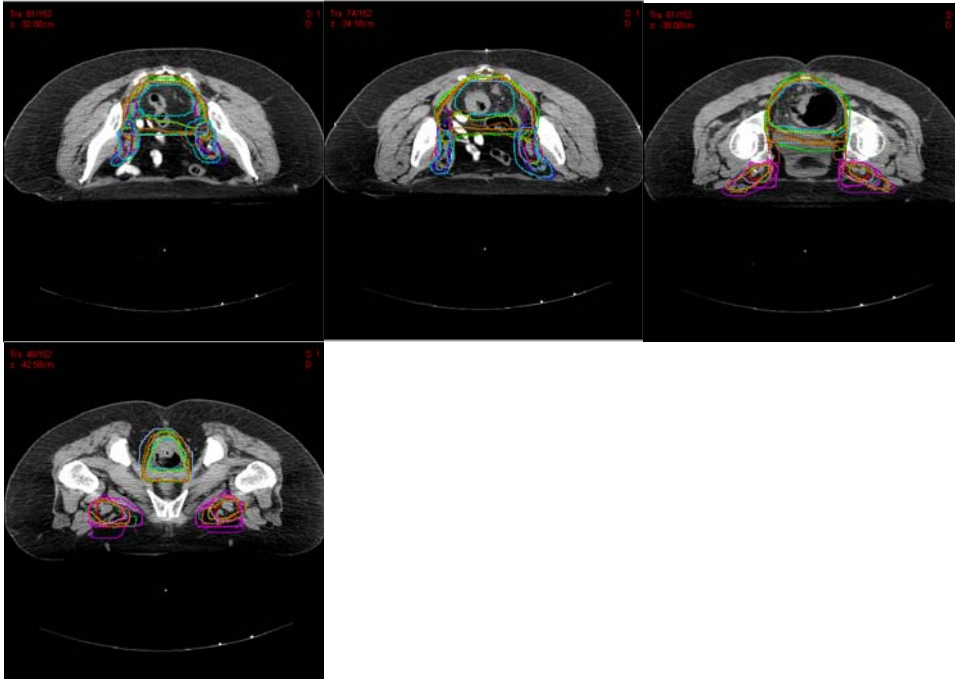


Figure 2. Group consensus contours: Brown = CTVA (peri-rectal, pre-sacral, internal iliac), Blue = CTVB (external iliac), Red = CTVC (inguinal). These are best viewed with a zoom of 200%

